



Protocol for the Examination of Excision Specimens From Patients With Invasive Melanoma of the Skin

Version: 1.1.0.0

Protocol Posting Date: June 2024

CAP Laboratory Accreditation Program Protocol Required Use Date: March 2025

The changes included in this current protocol version affect accreditation requirements. The new deadline for implementing this protocol version is reflected in the above accreditation date.

For accreditation purposes, this protocol should be used for the following procedures AND tumor types:

Procedure	Description
Excision	
Tumor Type	Description
Melanoma	Limited to invasive melanoma of cutaneous surfaces only

This protocol is NOT required for accreditation purposes for the following:

Procedure
Biopsy (consider Skin Melanoma Biopsy protocol)
Primary resection specimen with no residual melanoma (e.g., following neoadjuvant therapy)
Cytologic specimens

Authors

Priyadharsini Nagarajan, MD, PhD*; Wonwoo Shon, DO; Klaus J. Busam, MD; David P. Frishberg, MD; Jeffery E. Gershenwald, MD; Jeffrey North, MD; Victor G. Prieto, MD, PhD; Richard A. Scolyer, BMedSci, MBBS, MD; Thomas J. Flotte, MD; Timothy H. McCalmont, MD; Bruce Robert Smoller, MD.

With guidance from the CAP Cancer and CAP Pathology Electronic Reporting Committees.

* Denotes primary author.

Accreditation Requirements

This protocol can be utilized for a variety of procedures and tumor types for clinical care purposes. For accreditation purposes, only the definitive primary cancer resection specimen is required to have the core and conditional data elements reported in a synoptic format.

- Core data elements are required in reports to adequately describe appropriate malignancies. For accreditation purposes, essential data elements must be reported in all instances, even if the response is “not applicable” or “cannot be determined.”
- Conditional data elements are only required to be reported if applicable as delineated in the protocol. For instance, the total number of lymph nodes examined must be reported, but only if nodes are present in the specimen.
- Optional data elements are identified with “+” and although not required for CAP accreditation purposes, may be considered for reporting as determined by local practice standards.

The use of this protocol is not required for recurrent tumors or for metastatic tumors that are resected at a different time than the primary tumor. Use of this protocol is also not required for pathology reviews performed at a second institution (i.e., secondary consultation, second opinion, or review of outside case at second institution).

Synoptic Reporting

All core and conditionally required data elements outlined on the surgical case summary from this cancer protocol must be displayed in synoptic report format. Synoptic format is defined as:

- Data element: followed by its answer (response), outline format without the paired Data element: Response format is NOT considered synoptic.
- The data element should be represented in the report as it is listed in the case summary. The response for any data element may be modified from those listed in the case summary, including “Cannot be determined” if appropriate.
- Each diagnostic parameter pair (Data element: Response) is listed on a separate line or in a tabular format to achieve visual separation. The following exceptions are allowed to be listed on one line:
 - Anatomic site or specimen, laterality, and procedure
 - Pathologic Stage Classification (pTNM) elements
 - Negative margins, as long as all negative margins are specifically enumerated where applicable
- The synoptic portion of the report can appear in the diagnosis section of the pathology report, at the end of the report or in a separate section, but all Data element: Responses must be listed together in one location

Organizations and pathologists may choose to list the required elements in any order, use additional methods in order to enhance or achieve visual separation, or add optional items within the synoptic report. The report may have required elements in a summary format elsewhere in the report IN ADDITION TO but not as replacement for the synoptic report i.e., all required elements must be in the synoptic portion of the report in the format defined above.

Summary of Changes

v 1.1.0.0

- Added “specify site” to Tumor Site answer Skin of trunk
- Reporting of Macroscopic Satellite Lesion(s) status updated to optional
- Reporting of Histologic Type updated to conditional
- Added list item response answers to Anatomic (Clark) Level question
- Added optional Method of Detection questions for the presence of Lymphatic and / or Vascular Invasion and when Tumor present in regional lymph node(s) is selected
- Updated MARGINS section
- Updated answer to Nodal Site(s) with Tumor question
- pN Category staging correction and overall editing in conjunction with AJCC for improved clarity of classifications

Reporting Template

Protocol Posting Date: June 2024

Select a single response unless otherwise indicated.

CASE SUMMARY: (INVASIVE MELANOMA OF THE SKIN: Excision, Re-Excision)

Standard(s): AJCC-UICC 8

SPECIMEN

Procedure (Note A) (select all that apply)

- Excision
- Re-excision
- Sentinel node(s) biopsy
- Lymphadenectomy, regional nodes (specify): _____
- Other (specify): _____
- Not specified

Specimen Laterality

- Right
- Left
- Midline
- Not specified

TUMOR

Tumor Site (Note B)

- Skin, NOS: _____
- Skin of lip: _____
- External ear: _____
- Skin of other and unspecified parts of face: _____
- Skin of scalp and / or neck: _____
- Skin of trunk (specify site): _____
- Skin of upper limb and / or shoulder: _____
- Skin of lower limb and / or hip: _____
- Overlapping lesion of skin (specify sites): _____
- Penis: _____
 - Select all that apply*
 - + Prepuce
 - + Glans penis
 - + Body of penis
 - + Penis, NOS
- Scrotum: _____
- Vulva: _____
 - Select all that apply*
 - + Labium majus
 - + Labium minus

- + ___ Clitoris
- + ___ Vulva, NOS
- ___ Not specified

Multiple Primary Sites (required only if applicable)

- ___ Not applicable (no additional primary site(s) present)
- ___ Present: _____

Please complete a separate checklist for each primary site

+Macroscopic Satellite Lesion(s)

- ___ Not identified
- ___ Present
- ___ Cannot be determined: _____

Histologic Type (required only if applicable) (Note [C](#))

- ___ Not applicable
- ___ Low-cumulative sun damage (CSD) melanoma (including superficial spreading melanoma)
- ___ Lentigo maligna melanoma (high-CSD melanoma)
- ___ Desmoplastic melanoma, pure (greater than or equal to 90% desmoplastic melanoma)
- ___ Mixed desmoplastic / non-desmoplastic melanoma (less than 90% desmoplastic melanoma)
- ___ Spitz melanoma (malignant Spitz tumor)
- ___ Acral melanoma
- ___ Melanoma arising in a giant congenital nevus
- ___ Melanoma arising in a blue nevus
- ___ Nodular melanoma
- ___ Nevoid melanoma
- ___ Dermal melanoma
- ___ Melanoma, NOS
- ___ Other histologic type not listed (specify): _____

+Histologic Type Comment: _____

Maximum Tumor (Breslow) Thickness in Millimeters (mm) (Note [D](#))

- ___ Specify in Millimeters (mm): _____ mm
- ___ At least in Millimeters (mm): _____ mm

Tumor (Breslow) Thickness (explain): _____

- ___ Cannot be determined (explain): _____

Ulceration (Notes [D](#),[E](#))

- ___ Not identified
- ___ Present

+Extent of Ulceration in Millimeters (mm): _____ mm

- ___ Cannot be determined: _____

+Anatomic (Clark) Level (Note [D](#))

- ___ II (melanoma present in but does not fill and / or expand papillary dermis)
- ___ III (melanoma fills and expands papillary dermis)

- IV (melanoma invades reticular dermis)
- V (melanoma invades subcutis)
- At least level II (explain): _____
- At least level III (explain): _____
- At least level IV (explain): _____
- Cannot be determined (explain): _____

Mitotic Rate (Note [F](#))

- None identified: _____
- Specify number of mitoses per square Millimeter (mm): _____ mitoses per mm²
- Cannot be determined (explain): _____

Microsatellite(s) (Note [G](#))

- Not identified
- Present

+Margin Involvement by Microsatellite(s)

- Not identified
- Present
 - Select all that apply*
 - Peripheral: _____
 - Deep: _____
 - Other (specify): _____
 - Cannot be determined: _____
- Cannot be determined: _____

Lymphatic and / or Vascular Invasion (Note [H](#))

- Not identified
- Present
- +Method of Detection (select all that apply)**
 - Immunohistochemical study
 - H&E stain
 - Cannot be determined: _____

Neurotropism (Note [I](#))

- Not identified
- Present
- Cannot be determined: _____

+Tumor-Infiltrating Lymphocytes (Note [J](#))

- Not identified
- Present, non-brisk
- Present, brisk
- Cannot be determined: _____

+Tumor Regression (Note [K](#))

- Not identified

Present

+Margin Involvement by Tumor Regression

Not identified

Present

Select all that apply

Peripheral: _____

Deep: _____

Other (specify): _____

Cannot be determined: _____

Cannot be determined: _____

MARGINS (Note [L](#))

Margin Status for Melanoma (select all that apply)

All margins negative for melanoma (e.g., in situ, invasive, or satellite)

+Distance from Invasive Melanoma to Peripheral Margin

Specify in Millimeters (mm)

Exact distance: _____ mm

Greater than: _____ mm

At least (specify): _____ mm

Less than: _____ mm

Less than 1 mm

Other (specify): _____

Cannot be determined: _____

+Distance from Invasive Melanoma to Deep Margin

Specify in Millimeters (mm)

Exact distance: _____ mm

Greater than: _____ mm

At least (specify): _____ mm

Less than: _____ mm

Less than 1 mm

Other (specify): _____

Cannot be determined: _____

+Closest Margin(s) to Invasive Melanoma (select all that apply)

Peripheral: _____

Deep: _____

Other (specify): _____

Cannot be determined (explain): _____

+Distance from Melanoma In Situ to Peripheral Margin

Specify in Millimeters (mm)

Exact distance: _____ mm

Greater than: _____ mm

At least (specify): _____ mm

Less than: _____ mm

Less than 1 mm

Other (specify): _____

Cannot be determined: _____

Invasive melanoma present at margin

Margin(s) Involved by Invasive Melanoma (select all that apply)

- Peripheral: _____
 Deep: _____
 Other (specify): _____
 Cannot be determined (explain): _____

Margin involvement by melanoma in situ should be recorded if in situ disease is present in the specimen, and if margins are uninvolved by invasive melanoma.

Melanoma in situ present at margin#

Margin(s) Involved by Melanoma In Situ (select all that apply)

- Peripheral: _____
 Deep: _____
 Other (specify): _____
 Cannot be determined (explain): _____
 Other (specify): _____
 Cannot be determined (explain): _____

+Margin Comment: _____

REGIONAL LYMPH NODES (Note [M](#))

Regional Lymph Node Status

- Not applicable (no regional lymph nodes submitted or found)
 Regional lymph nodes present
 All regional lymph nodes negative for tumor
 Tumor present in regional lymph node(s)

+Method of Detection

- Immunohistochemical study
 H&E stain

Total Number of Lymph Nodes with Tumor

- Exact number (specify): _____
 At least (specify): _____
 Other (specify): _____
 Cannot be determined (explain): _____

Number of Sentinel Lymph Nodes with Tumor (required only if applicable)

- Not applicable (no sentinel lymph nodes examined)
 Exact number (specify): _____
 At least (specify): _____
 Other (specify): _____
 Cannot be determined (explain): _____

+Nodal Site(s) with Tumor (select all that apply)

- Subcapsular
 Intraparenchymal
 Other (specify): _____
 Cannot be determined: _____

Size of Largest Sentinel Node Metastatic Deposit (required only if applicable)

Specify in Millimeters (mm)

- Not applicable
- Exact size: _____ mm
- At least (specify): _____ mm
- Greater than: _____ mm
- Less than: _____ mm
- Other (specify): _____
- Cannot be determined (explain): _____

Size of Largest Non-Sentinel Node Metastatic Deposit (required only if applicable)

Specify in Millimeters (mm)

- Not applicable
- Exact size: _____ mm
- At least (specify): _____ mm
- Greater than: _____ mm
- Less than: _____ mm
- Other (specify): _____
- Cannot be determined (explain): _____

Extranodal Extension

- Not Identified
- Present
- Cannot be determined (explain): _____

Matted Nodes

- Not identified
- Present
- Other (specify): _____
- Cannot be determined (explain): _____
- Other (specify): _____
- Cannot be determined (explain): _____

Total Number of Lymph Nodes Examined (sentinel and non-sentinel)

- Exact number (specify): _____
- At least (specify): _____
- Other (specify): _____
- Cannot be determined (explain): _____

Number of Sentinel Nodes Examined

- Exact number (specify): _____
- At least (specify): _____
- Other (specify): _____
- Cannot be determined (explain): _____

+Regional Lymph Node Comment: _____

DISTANT METASTASIS

Distant Site(s) Involved, if applicable (select all that apply)

- Not applicable
- Skin, subcutaneous tissues, soft tissues including muscle and / or non-regional lymph nodes:

- Lung: _____
- Liver: _____
- Other non-CNS site(s): _____
- CNS site(s): _____
- Other (specify): _____
- Cannot be determined: _____

pTNM CLASSIFICATION (AJCC 8th Edition) (Note [N](#))

Reporting of pT, pN, and (when applicable) pM categories is based on information available to the pathologist at the time the report is issued. As per the AJCC (Chapter 1, 8th Ed.) it is the managing physician's responsibility to establish the final pathologic stage based upon all pertinent information, including but potentially not limited to this pathology report.

Prior Procedure Classification

In general, CAP cancer protocol case summaries are intended to guide reporting on the specimen that the pathologist is evaluating at that time. However, melanoma cases frequently include multiple procedures. Because of this, a prior procedure that was performed may affect the pathologic classification of the tumor. In order to represent this appropriately in the pathology report, information from prior procedures may be incorporated into the assignment of pathologic classification if it is available. When information from a prior procedure is included in this report, details of that procedure should be documented in the report as well.

- No information from a prior procedure is included in the classification assigned in this report
- Classification assigned in this report includes information from a prior procedure (explain):

Modified Classification (required only if applicable) (select all that apply)

- Not applicable
- y (post-neoadjuvant therapy)
- r (recurrence)

pT Category

- pT not assigned (cannot be determined based on available pathological information)
- pT0: No evidence of primary tumor (e.g., unknown primary or completely regressed melanoma)
pT1: Melanoma 1.0 mm or less in thickness, ulceration status unknown or unspecified (Note [D](#))
- pT1a: Melanoma less than 0.8 mm in thickness, without ulceration
- pT1b: Melanoma less than 0.8 mm in thickness with ulceration; or Melanoma 0.8 to 1.0 mm in thickness with or without ulceration
- pT1 (subcategory cannot be determined)
pT2: Melanoma greater than 1.0 to 2.0 mm in thickness, ulceration status unknown or unspecified
- pT2a: Melanoma greater than 1.0 to 2.0 mm in thickness, without ulceration
- pT2b: Melanoma greater than 1.0 to 2.0 mm in thickness, with ulceration
- pT2 (subcategory cannot be determined)
pT3: Melanoma greater than 2.0 to 4.0 mm in thickness, ulceration status unknown or unspecified
- pT3a: Melanoma greater than 2.0 to 4.0 mm in thickness, without ulceration
- pT3b: Melanoma greater than 2.0 to 4.0 mm in thickness, with ulceration

___ pT3 (subcategory cannot be determined)

pT4: Melanoma greater than 4.0 mm in thickness, ulceration status unknown or unspecified

___ pT4a: Melanoma greater than 4.0 mm in thickness, without ulceration

___ pT4b: Melanoma greater than 4.0 mm in thickness, with ulceration

___ pT4 (subcategory cannot be determined)

T Suffix (required only if applicable)

___ Not applicable

___ (m) multiple primary synchronous tumors in a single organ

pN Category

pN1b, 2b, and 3b subcategories are dependent on clinical information that may be unavailable to the pathologist. If this information is not available, the parent category (pN1, pN2 or pN3) should be selected.

___ pN not assigned (no nodes submitted or found)

___ pN not assigned (cannot be determined based on available pathological information)

___ pN0: No regional lymph node metastases detected and absence of in-transit, satellite and / or microsatellite metastases

pN1: One tumor-involved regional lymph node or in-transit, satellite, and / or microsatellite metastases with no tumor-involved regional lymph nodes

___ pN1a: One clinically occult tumor-involved regional lymph node (i.e., detected by sentinel lymph node biopsy) and absence of in-transit, satellite and / or microsatellite metastases

___ pN1b: One clinically detected tumor-involved regional lymph node and absence of in-transit, satellite and / or microsatellite metastases#

___ pN1c: No regional lymph node disease with presence of in-transit, satellite and / or microsatellite metastases

___ pN1 (subcategory cannot be determined)

pN2: Two or three tumor-involved regional lymph nodes or in-transit, satellite, and / or microsatellite metastases with one tumor-involved regional lymph node

___ pN2a: Two or three clinically occult tumor-involved regional lymph nodes (i.e., detected by sentinel lymph node biopsy) and absence of in-transit, satellite and / or microsatellite metastases

___ pN2b: Two or three tumor-involved regional lymph nodes, at least one of which was clinically detected and absence of in-transit, satellite and / or microsatellite metastases#

___ pN2c: One clinically occult or clinically detected tumor-involved regional lymph node with presence of in-transit, satellite and / or microsatellite metastases

___ pN2 (subcategory cannot be determined)

pN3: Four or more tumor-involved regional lymph nodes or in-transit, satellite, and / or microsatellite metastases with two or more tumor-involved regional lymph nodes, or any number of matted regional lymph nodes without or with in-transit, satellite, and / or microsatellite metastases

___ pN3a: Four or more clinically occult tumor-involved regional lymph nodes (i.e., detected by sentinel lymph node biopsy) and absence of in-transit, satellite and / or microsatellite metastases

___ pN3b: Four or more tumor-involved regional lymph nodes, at least one of which was clinically detected and absence of in-transit, satellite and / or microsatellite metastases; OR presence of any number of matted lymph nodes, and absence of in-transit, satellite and / or microsatellite metastases#

___ pN3c: Two or more clinically occult or clinically detected tumor-involved regional lymph nodes with presence of in-transit, satellite and / or microsatellite metastases; AND / OR any number of matted lymph nodes and presence of in-transit, satellite and / or microsatellite metastases

___ pN3 (subcategory cannot be determined)

pM Category (required only if confirmed pathologically)

AJCC suffixes for M category: (0) LDH not elevated, (1) LDH elevated, are not included in the surgical pathology report. LDH levels, as with other clinical parameters, may be included in the final classification by clinicians with access to this data.

Not applicable - pM cannot be determined from the submitted specimen(s)

pM1: Evidence of distant metastasis (documented in this specimen)

pM1a: Distant metastasis in skin (including subcutaneous tissues), soft tissues including muscle and / or non-regional lymph node(s)

pM1b: Distant metastasis to lung with or without M1a sites of disease

pM1c: Distant metastasis to non-CNS visceral sites with or without M1a or M1b sites of disease

pM1d: Distant metastasis to CNS with or without M1a, M1b, or M1c sites of disease

pM1 (subcategory cannot be determined)

ADDITIONAL FINDINGS

+Additional Findings (select all that apply)

Associated nevus (specify type): _____

Other (specify): _____

SPECIAL STUDIES

For molecular genetic reporting, the CAP Melanoma Biomarker Template should be used. Pending biomarker studies should be listed in the Comments section of this report.

COMMENTS

Comment(s): _____

Explanatory Notes

A. Procedure

Optimal pathologic evaluation of melanocytic lesions requires complete excision that incorporates the full thickness of the lesion removed intact.¹ 'Shave' procedures that do not include the intact base of the lesion are suboptimal for pathologic evaluation and should be avoided unless clinically indicated. Similarly, "punch" procedures may not include intact peripheral borders of the lesion thereby limiting assessment of symmetry and peripheral circumscription, which can be essential for distinction of melanoma from melanocytic nevus.^{2,3} Partial biopsies of melanocytic tumors are associated with an increased risk of misdiagnosis with possible consequent adverse clinical outcomes.⁴ Nevertheless, clinical factors are also important in determining the most appropriate biopsy technique for any lesion. For example, an excision biopsy of a large lesion on a cosmetically or functionally sensitive site may cause cosmetic disfigurement or alter reconstructive options.

The use of frozen sections for evaluation of biopsy or excision of melanocytic lesions is strongly discouraged.^{5,6} Optimal histologic evaluation of cutaneous melanoma requires well-oriented, well-fixed, well-cut, well-stained hematoxylin-and-eosin (H&E) sections prepared from formalin-fixed paraffin-embedded tissue. Frozen sections of sentinel lymph nodes are similarly discouraged, because the manipulation required for intraoperative handling may decrease the sensitivity of the procedure.⁷

References

1. Sober AJ, Chuang TY, Duvic M, et al. Guidelines of care for primary cutaneous melanoma. *J Am Acad Dermatol*. 2001;45(4):579-586.
2. Stell VH, Norton HJ, Smith KS, Salo JC, White RL, Jr. Method of biopsy and incidence of positive margins in primary melanoma. *Ann Surg Oncol*. 2007;14(2):893-898.
3. Sober AJ, Balch CM. Method of biopsy and incidence of positive margins in primary melanoma. *Ann Surg Oncol*. 2007;14(2):274-275.
4. Ng JC, Swain S, Dowling JP, Wolfe R, Simpson P, Kelly JW. The impact of partial biopsy on histopathologic diagnosis of cutaneous melanoma: experience of an Australian tertiary referral service. *Arch Dermatol*. 2010;146(3):234-239.
5. Smith-Zagone MJ, Schwartz MR. Frozen section of skin specimens. *Arch Pathol Lab Med*. 2005;129(12):1536-1543.
6. Prieto VG, Argenyi ZB, Barnhill RL, et al. Are en face frozen sections accurate for diagnosing margin status in melanocytic lesions? *Am J Clin Pathol*. 2003;120(2):203-208.
7. Scolyer RA, Thompson JF, McCarthy SW, Gershenwald JE, Ross MI, Cochran AJ. Intraoperative frozen-section evaluation can reduce accuracy of pathologic assessment of sentinel nodes in melanoma patients. *J Am Coll Surg*. 2005;201(5):821-823; author reply 823-824.

B. Anatomic Tumor Site

For cutaneous melanoma, prognosis may be affected by primary anatomic site.^{1,2,3}

References

1. Balch CM, Soong SJ, Gershenwald JE, et al. Prognostic factors analysis of 17,600 melanoma patients: validation of the American Joint Committee on Cancer melanoma staging system. *J Clin Oncol*. 2001;19(16):3622-3634.

2. Elder DE, Massi D, Scolyer RA, Willemze R. eds. *WHO Classification of Skin Tumors*. World Health Organization of Tumors, 4th ed Volume 11. Lyon France; 2018, ISBN-13 978-92-832-2440-2.
3. Elder DE, Bastian BC, Duncan LM, et al. *WHO Classification of Skin Tumors*. World Health Organization of Tumors, 5th ed (Beta version), 2023.

C. Melanoma Histologic Subtypes

The recent WHO 2018 classification¹ introduced multidimensional pathway classification of melanocytic tumors based on the extent of ultraviolet (UV) radiation damage, the cell of origin, and characteristic genomic findings, which was further refined in the WHO 2023 beta version² (Table 1).

Table 1. Classification of melanoma

Ultraviolet (UV) exposure	Pathway	Subtypes
Melanomas arising in sun-exposed skin		
	I	Low-CSD melanoma (including superficial spreading melanoma)
	II	High-CSD melanoma/lentigo malignamelanoma
	III	Desmoplastic melanoma
Melanomas arising at sun-shielded sites or without known etiological associations with UV radiation exposure		
	IV	Spitz melanoma (malignant Spitz tumor)
	V	Acral melanoma
	VI	Mucosal melanoma
	VII	Melanoma arising in congenital nevus
	VIII	Melanoma arising in blue nevus
	IX	Uveal melanoma
Variable		Nodular, nevoid, and dermal melanomas.

References

1. Elder DE, Massi D, Scolyer RA, Willemze R. eds. *WHO Classification of Skin Tumors*. World Health Organization of Tumors, 4th ed Volume 11. Lyon France; 2018, ISBN-13 978-92-832-2440-2.
2. Elder DE, Bastian BC, Duncan LM, et al. *WHO Classification of Skin Tumors*. World Health Organization of Tumors, 5th ed (Beta version), 2023.

D. Primary Tumor (Breslow) Thickness and Anatomic (Clark) Levels

Maximum tumor thickness is measured with a calibrated ocular micrometer at a right angle to the surface of the lesion at the point of measurement. The upper point of reference is the upper edge of the granular layer of the epidermis of the overlying skin (if intact) or, the base of the ulcer, if the lesion is ulcerated. The lower reference point is the deepest point of tumor invasion (i.e., the leading edge of a single mass or an isolated group of cells deep to the main mass). For primary melanomas lacking an intraepidermal component, the tumor thickness should be measured from the top of epidermal granular layer to the deepest invasive cell.

If the tumor is transected at the deep margin of the specimen, the depth may be indicated as “at least ___ mm” with a comment explaining the limitation of thickness assessment. For example, “The maximum tumor thickness cannot be determined in this specimen because the deep plane of the biopsy transects the tumor.”

Tumor thickness measurements should not be based on periadnexal extension (either periadnexal adventitial or extra-adventitial extension), except when it is the only focus of invasion. In that circumstance, Breslow thickness may be measured from the inner layer of the outer root sheath epithelium or inner luminal surface of sweat glands/ ducts, to the furthest extent of infiltration into the periadnexal dermis.

Microsatellites or foci of neurotropism or lymphovascular invasion should not be included in tumor thickness measurements.

In the 8th edition of the AJCC melanoma staging system,¹ it is recommended that tumor thickness measurements be recorded to the nearest 0.1 mm, not the nearest 0.01 mm, because of the impracticality and imprecision of measurements, particularly for tumors greater than 1 mm thick. Tumors less than or equal to 1 mm thick may be measured to the nearest 0.01 mm if practical, but should be reported to the nearest 0.1 mm (e.g., melanomas measured to be in the range of 0.75 mm to 0.84 mm are reported as 0.8 mm in thickness and hence T1b, and tumors 1.01 to 1.04 mm in thickness are reported as 1.0 mm).

While the principal T category tumor thickness ranges have been maintained in the AJCC 8th edition, T1 is now subcategorized by tumor thickness strata at a 0.8 mm threshold. Tumor mitotic rate as a dichotomous variable is no longer used as a staging category criterion for T1 melanomas. T1a melanomas are now defined as non-ulcerated and less than 0.8 mm in thickness. T1b melanomas are defined as 0.8-1.0 mm in thickness or ulcerated melanomas less than 0.8 mm in thickness.

Anatomic (Clark) levels are defined as follows:

- I Intraepidermal tumor only (i.e., melanoma in situ)
- II Tumor present in but does not fill and/or expand papillary dermis
- III Tumor fills and expands papillary dermis
- IV Tumor invades into reticular dermis
- V Tumor invades subcutis

Anatomic (Clark) level of invasion remains an independent predictor of outcome and is recommended by the AJCC to be reported as a primary tumor characteristic.¹ However, assessment of Clark levels is less

reproducible among pathologists than is tumor thickness, and Clark levels are not used in the AJCC staging system for pT status. Accordingly, Clark levels are included in this checklist as an optional data item.

References

1. Gershenwald JE, Scolyer RA, Hess KR, et al. *Melanoma of the skin*, In: Amin MB, Edge SB, Greene FL, et al. eds. *AJCC Cancer Staging Manual*. 8th ed. New York, NY: Springer; 2017.

E. Ulceration

Primary tumor ulceration has been shown to be a dominant independent prognostic factor in invasive cutaneous melanoma^{1,2} and if present, changes the pT category from T1a to T1b, T2a to T2b, etc., depending on the thickness of the tumor. The presence or absence of ulceration must be confirmed on microscopic examination.² Melanoma ulceration is defined as the combination of the following features: full-thickness epidermal defect (including absence of stratum corneum and basement membrane); evidence of reactive changes (i.e., fibrin deposition, neutrophils); and thinning, effacement, or reactive hyperplasia of the surrounding epidermis in the absence of trauma or a recent surgical procedure. Ulcerated melanomas typically show invasion through the epidermis, whereas non-ulcerated melanomas tend to lift the overlying epidermis.

Only non-traumatic (“tumorigenic”) ulceration should be recorded as ulceration. If ulceration is present related to a prior biopsy, the tumor should not be recorded as ulcerated for staging purposes. If a lesion has been recently biopsied or there is only focal loss of the epidermis, assessment of ulceration may be difficult or impossible; in this instance it may be difficult to determine whether the epidermal deficiency is due to true ulceration or to sectioning artifact.² Absence of fibrin, neutrophils, or granulation tissue from putative areas of ulceration would be clues that the apparent ulceration is actually due to sectioning of only part of the epidermis and this should not be designated as ulceration. If non-traumatic (“tumorigenic”) ulceration is present in either an initial partial biopsy or a re-excision specimen, then for staging purposes, the tumor should be recorded as ulcerated.

Ulceration may be present in an in situ melanoma but does not affect the staging.

A number of studies have demonstrated that the extent of ulceration (measured either as a percentage of the width of the dermal invasive component of the tumor or as a diameter/ width) more accurately predicts outcome than the presence or absence of ulceration alone.^{3,4}

References

1. Gershenwald JE, Scolyer RA, Hess KR, Sondak VK, Long GV, Ross MI et al. Melanoma staging: Evidence-based changes in the *American Joint Committee on Cancer eighth edition cancer staging manual*. *CA Cancer J Clin*. 2017;67(6):472-92.
2. Gershenwald JE, Scolyer RA, Hess KR, et al. *Melanoma of the skin*, In: Amin MB, Edge SB, Greene FL, et al. eds. *AJCC Cancer Staging Manual*. 8th ed. New York, NY: Springer; 2017.
3. Hout FE, Haydu LE, Murali R, Bonenkamp JJ, Thompson JF, Scolyer RA. Prognostic importance of the extent of ulceration in patients with clinically localized cutaneous melanoma. *Ann Surg*. 2012;255(6):1165-1170.
4. Namikawa K, Aung PP, Gershenwald JE, Milton DR, Prieto VG. Clinical impact of ulceration width, lymphovascular invasion, microscopic satellitosis, perineural invasion, and mitotic rate in

patients undergoing sentinel lymph node biopsy for cutaneous melanoma: a retrospective observational study at a comprehensive cancer center. *Cancer Med.* 2018;7(3):583-593.

F. Mitotic Rate

Tumor mitotic rate (of the invasive component of a melanoma) is a strong independent predictor of outcome across its dynamic range in all pT categories and should be assessed and recorded in all primary melanomas including in both initial biopsies and excisions (the highest value in either specimen should be used for prognostic purposes). Although tumor mitotic rate is no longer used as a T1-category criterion in the 8th edition of the AJCC melanoma staging system (due to the more significant prognostic significance of the new tumor thickness strata within T1 melanoma), mitotic rate will likely be an important parameter in prognostic models developed in the future that will provide personalized prediction of prognosis for individual patients.¹ The method recommended for enumerating the tumor mitotic rate in the 8th edition of the AJCC staging system is provided below:

“The recommended approach to enumerating mitoses is to first find the regions in the invasive melanoma within dermis containing the most mitotic figures, the so-called 'hot spot' or 'dermal hot spot.' After counting the mitoses in the initial high-power field, the count is extended to immediately adjacent non-overlapping fields until an area of tissue corresponding to 1 mm² is assessed. If no hot spot is found and mitoses are sparse and/or randomly scattered throughout the lesion, then a representative mitosis is chosen and, beginning with that field, the count is then extended to immediately adjacent non-overlapping fields until an area corresponding to 1 mm² of tissue is assessed. The count then is expressed as the (whole) number of mitoses/mm². If the invasive component of the tumor involves an area less than 1 mm², the number of mitoses should be assessed and recorded as if they were found within square millimeter. For example, if the entire dermal component of a tumor occupies 0.5 mm² and only one mitosis is identified, the mitotic rate should be recorded as 1/mm² (not 2/mm²). Only mitotic figures in invasive melanoma cells should be counted. The number of mitoses should be listed as a whole number per square millimeter. If no mitoses are identified, the mitotic rate may be recorded as “none identified” or “0/mm². This methodology for determining the mitotic rate of an invasive melanoma has been shown to have excellent interobserver reproducibility, including among pathologists with widely differing experience in the assessment of melanocytic tumors.²

To obtain accurate measurement, calibration of individual microscopes is recommended using a stage micrometer to determine the number of high-power fields that equates to a square millimeter.

The data that demonstrated the strong prognostic significance of mitotic rate were obtained from the melanoma pathology reports of routinely assessed H&E stained sections. It therefore is recommended that no additional sections be cut and examined in excess of those that would normally be used to report and diagnose the melanoma to determine the mitotic count (i.e., no additional sections should be cut and examined for the sole purpose of determining the mitotic rate, including in situations in which no mitoses are identified on the initial, routinely examined sections). Immunohistochemical stains for identifying mitoses are not used for determining mitotic rate for staging and/or reporting purposes. A possible exception is the use to dual immunohistochemistry (e.g., MART1 and pHH3) to determine if a cell in mitosis is a melanocyte or not (macrophage, endothelial cell, etc.).³

Although the AJCC recommends reporting “0” rather than “none identified” or “fewer than 1,” for the purposes of cancer registry reporting all of these terms should be considered equivalent.

References

1. Gershenwald JE, Scolyer RA, Hess KR, et al. Melanoma of the skin, In: Amin MB, Edge SB, Greene FL, et al. eds. *AJCC Cancer Staging Manual*. 8th ed. New York, NY: Springer; 2017.
2. Scolyer RA, Shaw HM, Thompson JF, et al. Interobserver reproducibility of histopathologic prognostic variables in primary cutaneous melanomas. *Am J Surg Pathol*. 2003;27(12):1571-1576.
3. Tetzlaff MT, Curry JL, Ivan D, et al. Immunodetection of phosphohistone H3 as a surrogate of mitotic figure count and clinical outcome in cutaneous melanoma. *Mod Pathol*. 2013;26(9):1153-1160.

G. Microsatellite(s)

A microsatellite(s) is defined as the presence of a microscopic discontinuous focus of melanoma adjacent or deep to a primary melanoma on pathological examination of the primary tumor site.¹ The metastatic tumor cells must be discontinuous from the primary tumor and separated from the primary tumor by normal stroma. If the tissue between the apparently separate nodule and the primary tumor is fibrotic and/or inflamed, this does not indicate a microsatellite, because the aforementioned changes may represent regression of the intervening tumor. There is no minimum size threshold or distance from the primary tumor to define a microsatellite. Before diagnosing the presence of a microsatellite, it is generally recommended that multiple sections from the same tissue block being examined to verify that the microsatellite is indeed discontinuous from the primary tumor. For example, periadnexal extension of tumor or the irregular shape of the peripheral or deep extent of the tumor may result in tumor that is contiguous with the primary tumor appear discontinuous on single sections.

Detecting a melanoma satellite metastasis at the periphery of an excision specimen often prompts consideration of a re-excision. This is based on the potential of satellite metastases to serve as sources of recurrence and to indicate the possible presence of additional melanoma beyond visible margins.

References

1. Gershenwald JE, Scolyer RA, Hess KR, et al. Melanoma of the skin, In: Amin MB, Edge SB, Greene FL, et al. eds. *AJCC Cancer Staging Manual*. 8th ed. New York, NY: Springer; 2017.

H. Lymphatic and/or Vascular Invasion

Lymphovascular invasion (LVI) is identified by the demonstration of melanoma cells within the lumina of blood vessels or lymphatics, or both.¹ Immunohistochemistry for vascular endothelial cell markers CD31, CD34, or ERG or the lymphatic marker D2-40 may assist in the identification of the presence of intravascular or intralymphatic melanoma by highlighting vascular lumina. Vascular invasion by melanoma correlates independently with worsened overall survival.² The detection of LVI is increased in primary melanomas when double labeling of tumor cells and lymphatic endothelium is applied (e.g.: MITF/D2-40, SOX10/D2-40, or SOX10/CD31).³

By AJCC/UICC convention, LVI does not affect the T category indicating local extent of tumor, i.e., foci of lymphovascular invasion should not be included in the measurement of tumor (Breslow) thickness.

References

1. Gershenwald JE, Scolyer RA, Hess KR, et al. Melanoma of the skin, In: Amin MB, Edge SB, Greene FL, et al. eds. *AJCC Cancer Staging Manual*. 8th ed. New York, NY: Springer; 2017.

2. Petersson F, Diwan AH, Ivan D, Gershenwald JE, Johnson MM, Harrell R, Prieto VG. Immunohistochemical detection of lymphovascular invasion with D2-40 in melanoma correlates with sentinel lymph node status, metastasis and survival. *J Cutan Pathol.* 2009;36(11):1157-1163.
3. Feldmeyer L, Tetzlaff M, Fox P, et al. Prognostic Implication of Lymphovascular Invasion Detected by Double Immunostaining for D2-40 and MITF1 in Primary Cutaneous Melanoma. *Am J Dermatopathol.* 2016;38(7):484-491.

I. Neurotropism

Neurotropism is defined as the presence of melanoma cells abutting nerve sheaths usually circumferentially (perineural invasion) or within nerves (intranerual invasion).¹ Occasionally, the tumor itself may form neuroid structures (termed 'neural transformation' and this is also regarded as neurotropism). Neurotropism is best identified at the periphery of the tumor; the presence of melanoma cells around nerves in the main tumor mass caused by "entrapment" of nerves in the expanding tumor does not represent neurotropism.

Neurotropism is most commonly identified in desmoplastic melanomas (sometimes termed desmoplastic neurotropic melanoma) but may occur in any melanoma subtype.² Neurotropism may correlate with an increased risk for local recurrence.

References

1. Gershenwald JE, Scolyer RA, Hess KR, et al. Melanoma of the skin, In: Amin MB, Edge SB, Greene FL, et al. eds. *AJCC Cancer Staging Manual.* 8th ed. New York, NY: Springer; 2017.
2. Elder DE, Massi D, Scolyer RA, Willemze R. eds. *WHO Classification of Skin Tumors.* World Health Organization of Tumors, 4th ed Volume 11. Lyon France; 2018, ISBN-13 978-92-832-2440-2.

J. Tumor-Infiltrating Lymphocytes

A paucity of tumor-infiltrating lymphocytes (TILs) is an adverse prognostic factor for cutaneous melanoma.¹ Tumor-infiltrating lymphocytes may be assessed in a semiquantitative way, as defined below. To qualify as TILs, lymphocytes need to surround and disrupt tumor cells of the invasive component of the tumor.

TILs Not Identified: No lymphocytes present, or lymphocytes present but do not infiltrate tumor at all.

TILs Non-brisk: Lymphocytes infiltrate melanoma only focally or not along the entire base of the invasive tumor.

TILs Brisk: Lymphocytes diffusely infiltrate the entire base of the invasive tumor (Figure 1, A) or show diffuse permeation of the invasive tumor (Figure 1, B).

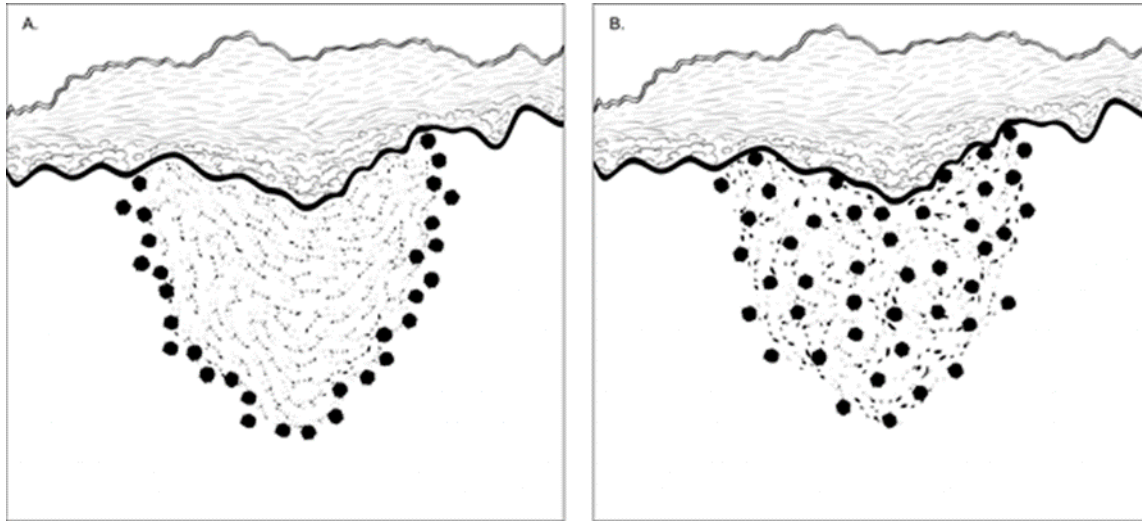


Figure 1. Brisk tumor-infiltrating lymphocytes in primary cutaneous melanoma. **A.** Lymphocytes diffusely infiltrate the entire base of the invasive tumor. **B.** Lymphocytes diffusely infiltrate the entire invasive component of the melanoma.

References

1. Crowson AN, Magro CM, Mihm MC. Prognosticators of melanoma, the melanoma report, and the sentinel lymph node. *Mod Pathol.* 2006;19(Suppl 2):S71-87.

K. Tumor Regression

Characteristic features of regression include replacement of tumor cells by lymphohistiocytic inflammation, as well as attenuation of the epidermis and non-laminated dermal fibrosis with inflammatory cells, melanophagocytosis, and telangiectasia¹.

Notably, when regression is observed at the peripheral excision margin, it prompts consideration for re-excision, as it suggests the possibility of residual melanoma beyond visible margins, necessitating comprehensive evaluation and if warranted, therapeutic intervention.

References

1. Aung PP, Nagarajan P, Prieto VG. Regression in primary cutaneous melanoma: etiopathogenesis and clinical significance. *Lab Invest.* 2017 Jun;97(6):657-668.

L. Margins

Microscopically measured distances between tumor and labeled peripheral (lateral) or deep margins are appropriately recorded for melanoma excision specimens, whenever possible. If a margin is involved by tumor, it should be stated whether the tumor is in situ or invasive. Occasionally, in situ melanoma can extend down an adnexal structure like a hair follicle and cause a deep positive margin.¹

References

1. Pozdnyakova O, Grossman J, Barbagallo, B, Lyle S. The hair follicle barrier to involvement by malignant melanoma. *Cancer* 2009;115:1267–1275.

M. Regional Lymph Nodes

Removal of sentinel lymph nodes may be performed for patients with clinically localized primary cutaneous melanomas with a thickness of 1 mm or greater, or in select patients with thinner tumors with other adverse prognostic features.^{1,2} Frozen section analysis of sentinel lymph nodes is not advised.¹ Review of the H&E-stained slides from multiple levels through serially sliced sentinel lymph nodes increases the sensitivity of detecting microscopic melanoma metastasis; routine analysis (H&E-stained sections of the cut surfaces of a simply bisected lymph node) may lead to a false-negative rate of 10%-15%. The use of immunohistochemical stains (e.g., for HMB45 or MART1/MelanA, SOX10, or melanocytic cocktails) further increases the sensitivity of detection of microscopic melanoma metastases and should also be considered in the examination of sentinel lymph nodes. Although immunohistochemical staining should be used in conjunction with and not in place of standard H&E histologic examination, immunohistochemically identified micrometastases are accepted as representing greater than N0 disease by the 8th edition of the AJCC staging system (as in the 7th edition), i.e., a lymph node in which any metastatic tumor cells are identified, irrespective of the number of cells or whether they were identified on H&E or immunostained sections, should be designated as a tumor-positive node.²

For histologic examination, whether for sentinel node analysis or for routine regional lymph node evaluation, the entire node, except tissue collected for consented research protocols (not advised for sentinel lymph nodes), should be submitted. For routine evaluation, large lymph nodes (greater than or equal to 5 mm) may be bisected or sliced at 2-3 mm intervals, whereas smaller nodes (less than 5 mm) may be submitted whole.

When metastasis is noted within the lymph node(s), it is recommended to measure the size of metastatic deposit.³ When there is only one focus of metastasis, the maximum 2 dimensions is measured in millimeters (mm) at right angles (Figure 2A and 2B). However, the determining size when multiple tumor foci are present within the lymph node can be rife with subjectivity; please see Figures 2C and 2D for recommendations. If there are multiple deposits, the aggregate dimension of the closely placed tumor deposits may be measured together (Figure 2C). If the tumor foci are widely spaced, then it is recommended to include only the tumor clusters that are located close to each other (Figure 2D) for measuring the size of metastatic tumor deposit within lymph node.

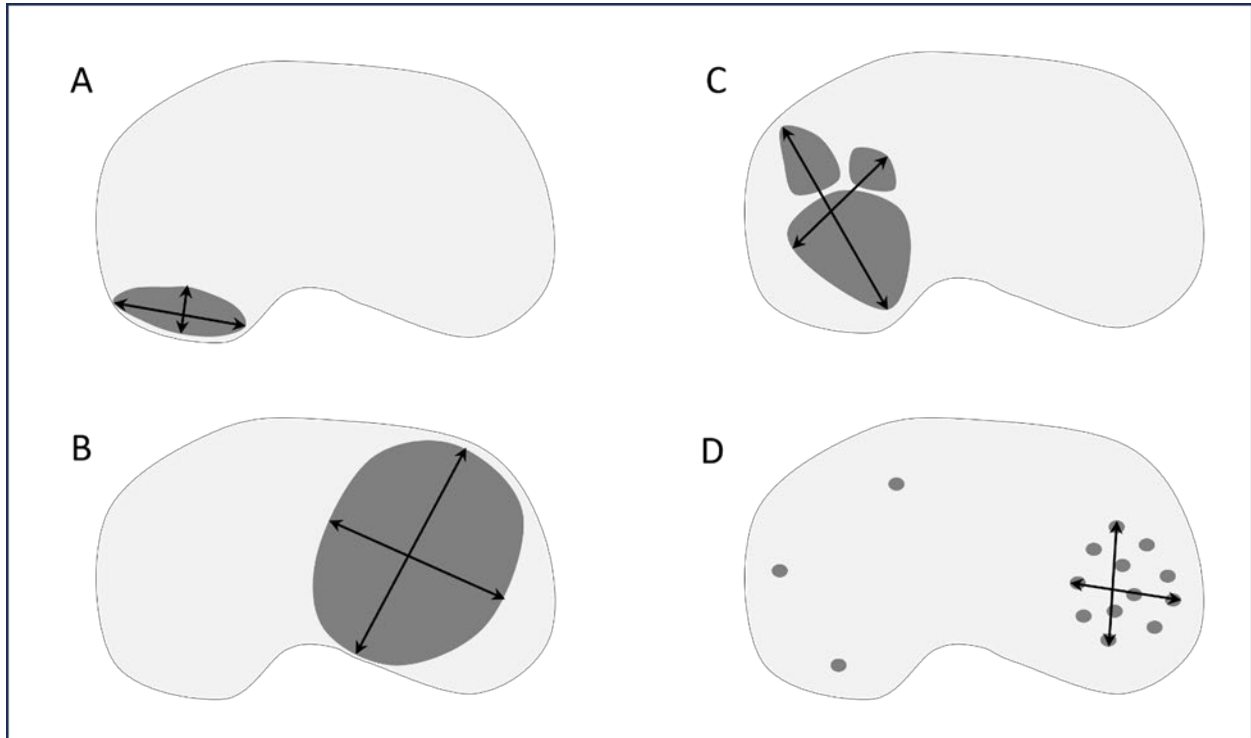


Figure 2. Measuring size of metastatic tumor deposits in lymph node. A. Single small subcapsular deposit of metastatic melanoma. B. Single large intraparenchymal deposit of melanoma. C. Multiple nests of metastatic melanoma, when located close together can be measured together. D. When there are multiple small metastatic foci, the ones closest to each other are measured in aggregate.

Data from multiple studies^{4,5,6} indicated that the sentinel lymph node tumor burden and/or the microanatomical region/compartiment of the sentinel node occupied by the metastasis may be useful in predicting patients who have additional disease in non-sentinel nodes as well as disease outcome. Because sentinel node tumor burden is considered a regional disease prognostic factor, it should be reported in all patients with a positive sentinel node, but it is not used to determine N-category groupings in the 8th edition of the AJCC staging system. The current National Comprehensive Cancer Network (NCCN) guidelines⁷ also recommend recording the size and location of tumor present in a positive sentinel node.

References

1. Scolyer RA, Thompson JF, McCarthy SW, Gershenwald JE, Ross MI, Cochran AJ. Intraoperative frozen-section evaluation can reduce accuracy of pathologic assessment of sentinel nodes in melanoma patients. *J Am Coll Surg.* 2005;201(5):821-823; author reply 823-824.
2. Gershenwald JE, Scolyer RA, Hess KR, et al. Melanoma of the skin, In: Amin MB, Edge SB, Greene FL, et al. eds. *AJCC Cancer Staging Manual.* 8th ed. New York, NY: Springer; 2017.
3. Prieto VG. Sentinel lymph nodes in cutaneous melanoma: handling, examination, and clinical repercussion. *Arch Pathol Lab Med.* 2010;134(12):1764-1769.
4. Gershenwald JE, Andtbacka RH, Prieto VG, et al. Microscopic tumor burden in sentinel lymph nodes predicts synchronous non-sentinel lymph node involvement in patients with melanoma. *J Clin Oncol.* 2008;26(26):4296-4303.

5. van Akkooi AC, Nowecki ZI, Voit C, et al. Sentinel node tumor burden according to the Rotterdam criteria is the most important prognostic factor for survival in melanoma patients: a multicenter study in 388 patients with positive sentinel nodes. *Ann Surg.* 2008;248(6):949-955.
6. Dewar DJ, Newell B, Green MA, Topping AP, Powell BW, Cook MG. The microanatomic location of metastatic melanoma in sentinel lymph nodes predicts non-sentinel lymph node involvement. *J Clin Oncol.* 2004;22(16):3345-3349.
7. Coit DG, Andtbacka R, Bichakjian CK, et al. Melanoma. *J Natl Compr Canc Netw.* 2009;7(3):250-275.

N. pTNM CLASSIFICATION

Changes in the 8th edition AJCC Cancer Staging Manual¹ of importance to practicing pathologists include:

- T1a melanomas are now defined as non-ulcerated melanomas less than 0.8 mm thick.
- T1b melanomas are now defined as melanomas between 0.8 mm and 1.0 mm in thickness OR ulcerated melanomas less than 0.8 mm thick.
- Tumor mitotic rate is no longer used as a T category criterion but remains an important prognostic factor and should be reported in all invasive primary melanomas.
- Recommendation to record tumor thickness to the nearest 0.1 mm (not the nearest 0.01 mm).
- Regarding regional lymph node metastasis, the previously empirically defined terms “microscopic” and “macroscopic” have been replaced with “clinically occult” (i.e., detected by sentinel node biopsy) and “clinically detected”.
- Non-nodal regional metastatic disease (i.e., microsattellites, satellites, and in transit metastases) are now formally stratified by N category according to the number of tumor-involved nodes
- Gross extranodal extension is no longer used as an N-category criterion (but presence of “matted nodes” retained).
- M1 is now defined by both anatomic site(s) of distant metastasis and serum LDH levels for all anatomic subsite categories of metastasis.
- New M1d designation has been added for distant metastasis to central nervous system.
- pT1bN0M0 is now pathologic stage IA in contrast to cT1N0M0 which remains clinical stage IB disease.
- N category now defines four stage subgroups and considers both T category elements and N category elements.

Pathologic staging includes microstaging of the primary melanoma and pathologic information about the regional lymph nodes after partial or complete lymphadenectomy.

In virtually all studies of cutaneous melanoma, tumor thickness has been shown to be a dominant prognostic factor, and it forms the basis for the stratification of pT category. Although anatomic (Clark) levels, commonly used to indicate extent of invasion of the primary tumor, are less predictive of clinical outcome than mitotic activity or ulceration.^{1,2,3}

By AJCC convention, the designation “T” refers to a primary tumor that has not been previously treated. Similarly, by convention, clinical staging is performed after biopsy of the primary melanoma (including utilizing pathologic information on microstaging of the primary melanoma) with clinical or biopsy assessment of regional lymph nodes and distant sites. Pathologic staging uses information gained from pathologic evaluation of both the primary melanoma after biopsy and wide excision as well as

pathological evaluation of the regional node basin after SLN biopsy (required for N categorization of all greater than T1 melanomas) and/or regional lymphadenectomy.^{1,2} In addition, for pathological staging, if information from any prior biopsy is known and is relevant for staging, this should be documented in the pathology report (in the staging section) and used for assigning T, N, and M categories and staging purposes.

T Category Considerations

Pathologic (microscopic) assessment of the primary tumor is required for accurate staging. Therefore, excision of the primary tumor, rather than incisional/partial biopsy, is advised. The T classification of melanoma is based on the thickness of the primary tumor and presence or absence of ulceration (see also Notes D, and E).

N Category Considerations (see also Note M)

The regional lymph nodes are the most common sites of metastasis. The widespread use of cutaneous lymphoscintigraphy, lymphatic mapping, and sentinel lymph node biopsies has greatly enhanced the ability to identify the presence of lymph node metastasis. By convention, the term regional lymph nodal metastasis refers to disease confined to one draining nodal basin or 2 contiguous draining nodal basins, such as combinations of inguino-femoral, femoral/iliac, axillary/supraclavicular, cervical/supraclavicular, axillary/femoral, or bilateral axillary or bilateral inguino-femoral metastases. In some patients, lymphoscintigraphic imaging may define multiple regional lymph node basins and disease identified in any of such basins also constitutes regional disease. Metastasis to non-draining nodal basin(s) is considered M1 disease.

Sentinel Lymph Nodes

Sentinel lymph node identification and evaluation is often included in the surgical approach to cutaneous melanoma.^{1,2} A sentinel lymph node is defined as any lymph node receiving direct lymphatic drainage from a primary tumor site. There is often more than 1 sentinel node per draining basin and in some patients, lymph may drain to more than one regional nodal basins.⁴ The clinical rationale for sentinel lymph node identification and separate evaluation assumes that metastatic involvement of a sentinel node is more likely than in other regional nodes in the same nodal basin that receive lymphatic drainage from the primary melanoma (non-sentinel lymph nodes). Conversely, if sentinel nodes are negative, other regional nodes in the same basin would be less likely to contain metastasis.

M Category Considerations

The category “MX” has been eliminated from the AJCC/UICC TNM system.¹ Unless there is clinical or pathologic evidence of distant metastasis, the stage is classified as clinical M0 (i.e., no distant metastasis). pM should only be reported when metastases have been documented by pathologic examination, pM1 disease. pMX and pM0 should not be reported by the pathologist.

TNM Descriptors

For identification of special cases of TNM or pTNM classifications, the “y,” “r,” and “a” prefixes are used. Although they do not affect the stage grouping, they indicate cases needing separate analysis.

Post-therapy or post-neoadjuvant therapy classification (yTNM) documents the extent of the disease for patients whose first course of therapy includes systemic or radiation treatment prior to surgical resection or when systemic therapy or radiation is the primary treatment with no surgical resection. The extent of

disease is classified using the same T, N, and M definitions and identified as post-treatment with a “yc” or “yp” prefix (ycT, ycN, ycTNM; ypT, ypN, ypTNM).

Recurrence or re-treatment classification (rTNM) may be used to define information gleaned from therapeutic procedures and from extent of disease defined clinically and may be prognostic for patients with recurrent cancer after a disease-free interval. It is important to understand that the rTNM classification does not change the original clinical or pathologic staging of the case and that this classification schema is not yet widely used in melanoma.^{1,2}

Autopsy classification (aTNM) is used to stage cases of cancer not recognized during life and only recognized postmortem.

Pretreatment Serum Lactate Dehydrogenase and Serum Albumin

Data from numerous studies have indicated that an elevated serum level of lactate dehydrogenase (LDH) is an independent predictor of decreased survival in AJCC stage IV melanoma patients. In the AJCC 8th edition, serum LDH is now recorded as “non-elevated” or “elevated” for each M category using the suffix, “(0)” or “(1)”, respectively.^{1,2}

References

1. Gershenwald JE, Scolyer RA, Hess KR, et al. Melanoma of the skin, In: Amin MB, Edge SB, Greene FL, et al. eds. *AJCC Cancer Staging Manual*. 8th ed. New York, NY: Springer; 2017.
2. Gershenwald JE, Scolyer RA, Hess KR, Sondak VK, Long GV, Ross MI et al. Melanoma staging: Evidence-based changes in the American *Joint Committee on Cancer eighth edition cancer staging manual*. *CA Cancer J Clin*. 2017;67(6):472-92.
3. Elder DE, Massi D, Scolyer RA, Willemze R. eds. *WHO Classification of Skin Tumors*. World Health Organization of Tumors, 4th ed Volume 11. Lyon France; 2018, ISBN-13 978-92-832-2440-2.
4. Gershenwald JE, Ross MI. Sentinel lymph node biopsy for cutaneous melanoma. *N Eng J Med* 364(18):1738-45, 2011. e-Pub 5/2011.